

# Development of High-Precision Three-Dimensional Images for Colonoscopy

Ogura K<sup>a</sup>, Bando H<sup>\*a,b,c</sup>, Obonai T<sup>a</sup>, Kato Y<sup>a</sup> and Kato Y<sup>a</sup>

<sup>a</sup>Kanaiso Hospital, Komatsushima, Tokushima, Japan

<sup>b</sup>Tokushima University / Medical Research, Tokushima, Japan

<sup>c</sup>Shikoku Division of Integrative Medicine Japan (IMJ), Japan

## Article Info

### Article History:

**Received:** 30 December 2021

**Accepted:** 02 January 2022

**Published:** 05 January 2022

**\*Corresponding author:** Bando H, Tokushima University, Medical Research, Nakashowa 1-61, Tokushima 770-0943 Japan; DOI: <https://doi.org/10.36266/IJCR/CI/170>

## Abstract

**Background:** For three-dimensional image analysis, SYNAPSE VINCENT (Fujifilm, Japan) has been applied. Authors have continued various clinical practice and research with image study by computer analysis.

**Patient and Method:** The patient is a 65-year-old female with further evaluation of colon. Method included abdominal computed tomography (CT) scan associated with injecting necessary amount of air from the anus. With maintaining this condition, CT scan was conducted two times of supine position and prone position.

**Results:** The case had sigmoid cancer, which was presented irregular surface texture. Further, she had colon polyp in the sigmoid colon and diverticula in the descending colon. These images were presented in the display associated with i) the position and direction for observation, ii) CT image of the corresponding point, iii) endoscopic image for the corresponding region.

**Discussion:** This image analysis system would be useful for clinical diagnosis, because the images have multiple angles and related situations of colon mucosa, folds, and stiffness and so on. The combined data can provide significant information including coronal, horizontal and sagittal planes. When the surgeon operates colon cancer, he can make the correct imagination of the lesion in advance. It seems to be beneficial for smooth treatment of surgical operation.

**Keywords:** Three-Dimensional Image Analysis; SYNAPSE Vincent; Computed Tomography Colonography (CTC); Colorectal Cancer (CRC); Gastrografen

**Copyright:** © 2022 Bando H, et al. This is an open-access article distributed under the terms of the Creative Commons Attribution License, which permits unrestricted use, distribution, and reproduction in any medium, provided the original author and source are credited.

## Introduction

For medical diagnostic imaging, Computed tomography (CT), magnetic resonance imaging (MRI) and magnetic resonance angiography (MRA) have been widely known and prevalent. Recent development includes three-dimensional image analysis for more detail data [1]. Among them, SYNAPSE VINCENT (Fujifilm, Tokyo, Japan) has been used for clinical practice [2]. The authors have continued to treat various patients for years, and high-level diagnostic imaging has been applied for diabetes, kidney disease, dialysis patients, orthopedic patients, and so on [3,4]. Especially in the radiology department, new technologies such as reconstruction image methods have been applied and reported so far [5]. We have experienced an impressive case associated with detail image analysis, which is presented in this article.

## Case Presentation

### Patient and Method

The patient is a 65-year-old female. As a medical history, colorectal polyps have been pointed out before, but there is no particular complaint at present. No abnormal findings were found on blood, chest XP, or electrocardiogram. She hoped to have further evaluation for colon disease.

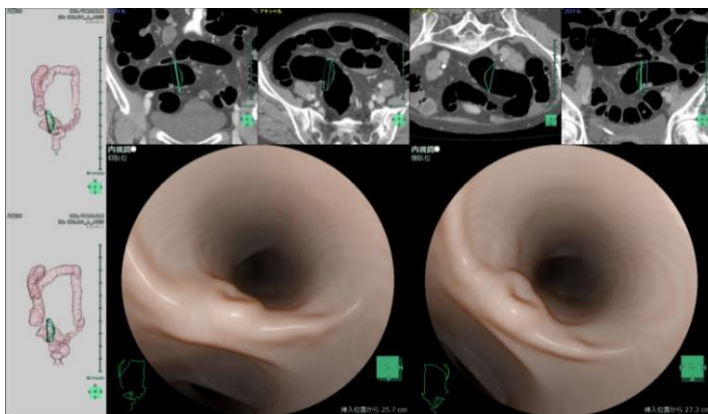
The method was to perform abdominal CT to observe the condition of colon mucosa. On the day before the examination, she took some laxative and gastrografen (Diatrizoate, amidotrizoate) per os for preparation. It can reduce the amount of stool that is present in the intestinal tract. Further, gastrografen is beneficial for clear image reconstruction, because the data of remaining gastrografen can be calculated for subtraction. When taking a CT scan of the abdomen, inject enough amount of air from the anus. This method is similar to the use of barium and air in routine enema examinations. For this time, no barium is used, and only air is injected. Then, the CT examination is performed twice at the supine position and prone position. Thus, CT examination was performed for this patient. Then, these data are analyzed by SYNAPSE VINCENT (Fujifilm, Tokyo, Japan).

## Results

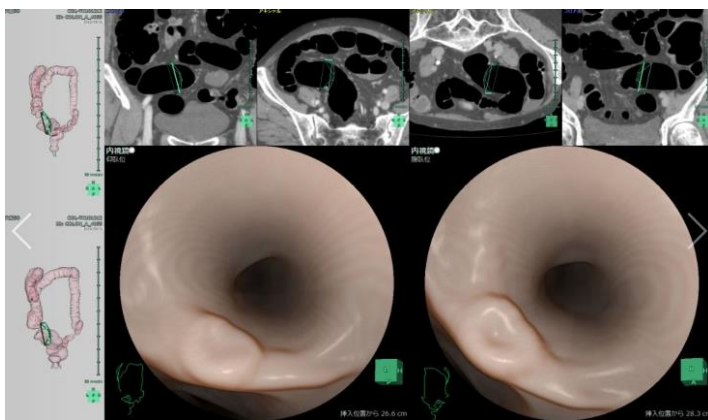
The results of image analysis using SYNAPSE VINCENT for colon are shown in Fig. 1-5. In each figure, three components are included as follows: left; the position and direction for observation, upper; CT image of the corresponding point, and lower; endoscopic image for the corresponding region. CT and endoscopic image are presented as supine and prone position (left/right), respectively.

### Cancer of Sigmoid Colon

Analyzed data in the sigmoid colon are shown in (Figure 1 and 2). A elevated irregular lesion is observed on the mucosa of the colon, which is a distance view (Figure 1). A depression is found in the central part, and the surface texture has an irregular image. A closer image was obtained for the colon lesion in Figure 2. The irregular surface with elevated and depressed mucosa was recognized more clearly. This lesion was later diagnosed as sigmoid colon cancer by pathological examination. Since the condition and positional relationship of the lesion could be evaluated in advance as well as detail situation of surrounding mucosa, it provided beneficial information to fully prepare for the surgical operation.



**Figure 1:** Sigmoid colon indicating the presence of raised lesion with depression for distance view.

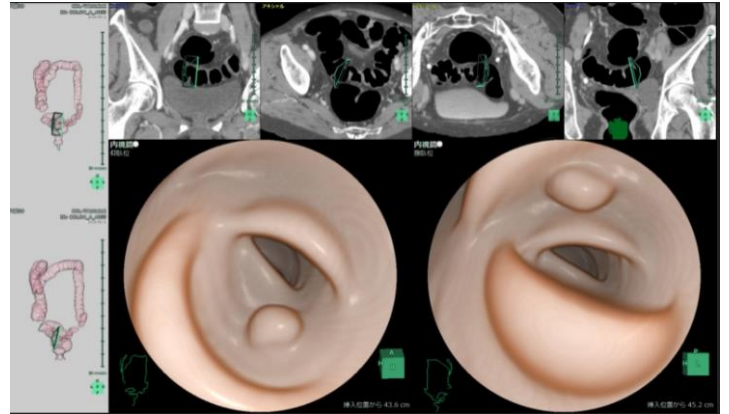


**Figure 2:** Sigmoid colon indicating irregular lesion with depression for near view.

### Polyp Lesions

For this case, other polyp was also observed in the sigmoid colon (Figure 3). The surface of the polyp is smooth, suggesting a benign

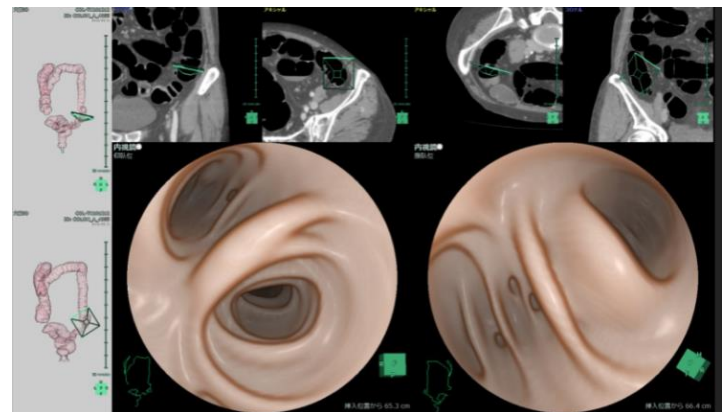
polyp. When observing both the left figure and the right figure of the endoscopic image of Figure 3, the location of the polyp is different by 180 degrees, which is a meaningful angle. Left figure is on supine position, and right figure is on prone positions as CT image and endoscopic data.



**Figure 3:** colon polyp in the descending colon from supine and prone points of view.

### Diverticulum of the Colon

In the transition region between the sigmoid colon and descending colon, three diverticula are clearly shown (Figure 4). Figure 4 shows the detail situation of diverticula at distal point of descending colon. For these diverticula, distance and near image can be observed, showing related folds and surrounding mucosa.



**Figure 4:** Diverticula of the colon in the descending colon.

### Clear Image of Right Colon Flexion

The right colon flexion (liver curve) is situated at the transition point between the ascending colon and the transverse colon. Mucosa situation of this point can be clearly observed in Figure 5. Left and right views of Figure 5 are from supine and prone position, respectively.

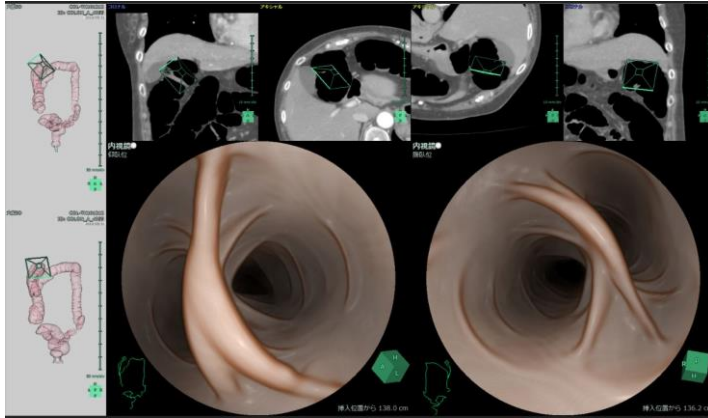


Figure 5: Clear image of right colon flexion from supine and prone position.

## Discussion

In this report, significant development of medical image analysis system and related clinical application for patient with colon disease are described. The discussion has three parts, which are i) image analysis system of SYNAPSE VINCENT, ii) perspectives for characteristic points in this case regarding figure 1-5, and iii) latest reference of diagnostic imaging for colon.

## Image Reconstruction System

Regarding medical image analysis system, Fujifilm Medical Co., Ltd. has been known and evaluated [2]. It has provided "SYNAPSE VINCENT" as a volume analyzer that draws high-precision 3D images from tomographic images of CT and MRI. SYNAPSE VINCENT continues to develop analysis technology for various organs of the body so far. The current version is equipped with an application using automatic intelligence of deep learning. As the latest function, the lumbar nerve can be clearly extracted by combining bone CT and lumbar nerve MRI. Further, brain MRI image can be analyzed for 15 areas by automatically extraction.

The technique presented in this paper is useful for radiodiagnosis in luminal organs. A similar case is the preoperative evaluation of superficial ductal spread (SDS) in perihilar cholangiocarcinoma (PCCA) [6]. The method is based on the previous magnetic resonance cholangiopancreatography (MRCP) [7]. It is difficult to judge the superficial ductal spread (SDS) by this alone [8]. Therefore, a 3-D image is created using the Two-dimensional (2D) image acquired by MRCP. These methods are called magnetic resonance cholangioscopy (MRCS), and MRCS makes it possible to visualize the running of the bile duct in all directions. It has also been clinically applied to bronchoscopes that display images of the lumen construction [9].

## Perspectives for Characteristic Points

When various image data are observed in the display, we formerly had to understand the position and direction of endoscopy and construct three-dimensional space (3-D) image by our imagination and recognition. On the other hand, this system can show

simultaneously several factors for real time (Figure 1,2). They include i) mucosa image of the colon, ii) the position where the tip of the colonoscope is located, and iii) the direction in which the endoscope faces. Consequently, this image system with all in one for the display would be useful for patient, family, physician and other related medical staffs.

The image of the polyp was found from different angles, which is from supine position and prone position (Figure 3). Further, surrounding mucosa of the polyp with peristaltic movement is different. Then, this combination allows us to understand the movement of the folds of colon and its relationship with polyps. By combining a distant view, a near view and examining CT images, it will be possible to easily understand the positional relationship and directionality. When actually observing and simultaneously moving the endoscopic image with a computer, the focused lesion by patient's coronal and transverse CT views can move in synchronization with the movement. This is very useful in clinical practice, diagnosis and treatment.

In this case, diverticula in the descending colon and clear image of hepatic curve were observed (Figure 4,5). By the reconstruction of the image, the depth, size and shape of the diverticula can be judged precisely. Recent report is found concerning diverticula. Using Computed tomography colonography (CTC), the detail situation of colonic diverticula was investigated in Japan [10]. The study was from Japanese National Computed Tomographic Colonography Trial, with 1181 cases from 14 hospitals. As a result, 48.1% cases had diverticulosis with higher prevalence in older people. Younger people tend to have right-sided, and older have bilateral type diverticulosis. These data were higher than previous reports. The proportion of people who have diverticula seems to increase by applying this method in the future.

## Latest Diagnostic Imaging for Colon

Several recent reports on colon cancer have been found. For preoperative patients with colorectal cancer, image and laboratory data were investigated [11]. Cases included 127 cases with 71 years in median. Psoas volume index (PVI) was positively correlated with BMI, handgrip strength and controlling nutritional status (CONUT) score. In latest study, the relationship of tumor extent of colorectal cancer (CRC) and image of CT colonography (CTC) was investigated [12]. Using CTC data in virtual colon dissection (VCD), circumferential tumor extent rate (CER) was calculated. Subjects were 195 consecutive patients of 64.7 years old in average with CRC, and CER was significantly correlated with stage of CRC. This finding suggests the clinical usefulness of CTC.

Furthermore, image analysis is beneficial for investigating blood vessels. By using high-resolution CT scans and analyzing data, anatomical states of the arteries and veins of the right colon were studied [13]. Patients (n=165) were received laparoscopic colectomy of right colon cancer. Preoperative CT images were created into multiplanar reformation and volume rendering images. As a result, 71.2% cases showed that right branch of middle colic

artery (MCA) has accessory right colic vein (ARCV). For colonoscopy, luminal surface of microvascular status can be observed, but the depth of blood vessels cannot be judged [14]. Microvessels of crypts and mucosa situation can be found from generated 3D image analysis using Synapse VINCENT [15,16]. In summary, the medical image analysis system and its application were described. By utilizing SYNAPSE VINCENT, cancer, polyps and diverticula of colon are clearly projected. This technique reduces the burden on the patient and provides a lot of useful information. The combined data can provide significant information including coronal, horizontal and sagittal planes. When the surgeon operates colon cancer, he can make the correct imagination of the lesion in advance. It seems to be beneficial for smooth treatment of surgical operation. Further developmental research would be expected in the future.

## References

1. Apriawan T, Bajamal AH, Hermawan Y, Fitra F, Darlan D, Kamal IH, et al. Three-dimensional (3D)-printed model reconstruction in pre-operative planning for wooden penetrating brain injury. *Bioprinting*. 2021; 24: e00168.
2. Fujifilm Medical. SYNAPSE VINCENT system.
3. Bando H. Perspectives on Sarcopenia and Protein Intake in Aged and Diabetic Patients. *J Health Care and Research*. 2021; 2: 122-125.
4. Kato Y, Bando H and Kato Y. Latest Perspectives Concerning Renal Rehabilitation for Chronic Kidney Disease (CKD). *J Cardiol Cardiovascular Res*. 2021; 1: 112.
5. Ogura K, Bando H, Kato Y. Clearer image of computed tomography by reconstruction analysis method. *Prac Clin Invest*. 2019; 1: 33-37.
6. Okuno M, Mukai T, Iwata S, Tezuka R, Mita N, Uemura S, et al. Preoperative perihilar cholangiocarcinoma assessment using virtual endoscopic imaging magnetic resonance cholangioscopy. *Endosc Int Open*. 2021; 9: E1158-E1163.
7. Hintze RE, Abou-Rebyeh H, Adler A, Veltzke-Schlieker W, Felix R, Wiedenmann B. Magnetic resonance cholangiopancreatography-guided unilateral endoscopic stent placement for Klatskin tumors. *Gastrointest Endosc*. 2001; 53: 40-46.
8. Lee SS, Kim MH, Lee SK, Kim TK, Seo DW, Park JS, et al. MR cholangiography versus cholangioscopy for evaluation of longitudinal extension of hilar cholangiocarcinoma. *Gastrointest Endosc*. 2002; 56: 25-32.
9. Kitamura A, Okafuji K, Imai R, Murakami M, Ro S, Tomishima Y, et al. Reproducibility of peripheral branches in virtual bronchoscopic navigation using VINCENT and LungPoint software for peripheral lung lesions. *Respir Investig*. 2021; 59: 772-776.
10. Isohata N, Nagata K, Utano K, Nozaki R, Nozu S, Kato T, et al. Recent trends in the prevalence and distribution of colonic diverticula in Japan evaluated using computed tomography colonography. *World J Gastroenterol*. 2021; 27: 4441-4452.
11. Tanaka K, Taoda A, Kashiwagi H. The associations between nutritional status, physical function and skeletal muscle mass of geriatric patients with colorectal cancer. *Clin Nutr ESPEN*. 2021; 41: 318-324.
12. Tsurumaru D, Takatsu N, Kai S, Oki E, Ishigami K. Measurement of circumferential tumor extent of colorectal cancer on CT colonography: relation to clinicopathological features and patient prognosis after surgery. *Jpn J Radiol*. 2021; 39: 966-972.
13. Obara N, Yamaguchi S, Okada Y. A Study of the Right Colonic Vascular Anatomy: Correlations between Veins and Arteries. *J Anus Rectum Colon*. 2021; 5: 306-312.
14. Koyama F, Ueda T, Morita K, Fujii H, Teramura Y, Obayashi C, Sho M. The existence of an endoscopically observable capillary plexus in the deep colonic mucosa. *Endoscopy*. 2021; 53: E417-E418.
15. Ohshima S. Volume analyzer SYNAPSE VINCENT for liver analysis. *J Hepatobiliary Pancreat Sci*. 2014; 21: 235-238.
16. Ueda T, Morita K, Koyama F, Teramura Y, Nakagawa T, Nakamura S, et al. A detailed comparison between the endoscopic images using blue laser imaging and three-dimensional reconstructed pathological images of colonic lesions. *PLoS One* 2020; 15: e0235279.