

# Remarkable Improvement of Periodontal Diseases (PD) and Diabetic State with Weight Reduction by Super Low Carbohydrate Diet (LCD)

Sakamoto D<sup>a</sup>, Bando H<sup>b</sup>, Iwatsuki N<sup>a</sup>, Sakamoto K<sup>a</sup>, Okada M<sup>a</sup> and Ogawa T<sup>a</sup>

<sup>a</sup>Sakamoto Hospital, Higashi Kagawa city, Kagawa, Japan

<sup>b</sup>Tokushima University, Medical Research, Tokushima, Japan

## Article Info

### Article History:

Received: 14 June, 2020

Accepted: 23 June, 2020

Published: 29 June, 2020

\*Corresponding author: Bando H,  
Tokushima University, Medical  
Research, Tokushima, Japan; Tel: +81-  
90-3187-2485; E-mail:  
[pianomed@bronze.ocn.ne.jp](mailto:pianomed@bronze.ocn.ne.jp)

## Abstract

The case was 57-year-old male with the past history of post-operation of Tetralogy of Fallot (TOF) at 11 years old. For dental problems, he visited a dentist and was diagnosed as periodontal diseases (PD) and Type 2 diabetes mellitus (T2DM) with 7.8% of HbA1c. His teeth showed moderate to severe PD and chronic periapical periodontitis due to carious teeth. He was treated for PD and T2DM in dental and internal medicine departments of the hospital. As our formula meal, super low carbohydrate diet (LCD) with 12% of carbohydrate ratio was started. Then, his weight decreased from 100kg to 90 kg in 3 months and HbA1c decreased from 7.8% to 5.4% in 4 months with normalized C-reactive protein (CRP) value. His clinical progress was satisfactory with effective results of dental treatment and LCD. Recent consensus guidelines by International Diabetes Federation (IDF) and European Federation of Periodontology (EFP) recommend the both treatments of PD and diabetes by dentist and internist together. Authors have continued clinical practice and research for years concerning LCD through Japan LCD promotion association (JLCDPA). This case would become some reference from PD and diabetic points of view.

**Keywords:** Tetralogy of Fallot (TOF); Periodontal diseases (PD); Low carbohydrate diet (LCD); International diabetes federation (IDF); European federation of periodontology (EFP); Japan LCD promotion association (JLCDPA)

**Copyright:** © 2020 Sakamoto D, et al. This is an open-access article distributed under the terms of the Creative Commons Attribution License, which permits unrestricted use, distribution, and reproduction in any medium, provided the original author and source are credited.

## Introduction

Diabetes has been one of the crucial diseases worldwide. It brings various influences of macroangiopathy, microangiopathy, dental complications, and so on [1]. Its therapy has been studied and proposed by standard method by American Diabetes Association (ADA) and the European Association for the Study of Diabetes (EASD), and others [2]. Especially, when there is combined status of diabetes and periodontal diseases (PD), we had to pay attention to the mutual vicious cycle [3]. Consequently, authors and collaborators have continued combined clinical practice with dentistry and internal medicine departments for patients with PD and diabetes [1,3]. Concerning this perspective, the consensus guideline was found by International Diabetes Federation (IDF) and European Federation of Periodontology (EFP) [4, 5].

On the other hand, the fundamental therapy for diabetes has been nutritional treatment [6]. Formerly, the diet therapy was conducted by Calorie Restriction (CR). After that, Low Carbohydrate Diet (LCD) has been introduced into medical and health care regions by well-known doctors, which were Drs. Atkins and Bernstein [7,8]. Consequently, LCD has been rather prevalent in Europe and United States [9]. In recent years, clinical beneficial effects of LCD have been reported for

glucose, lipids and arteriosclerotic disease [10].

Successively, LCD was initiated in Japan by our collaborators [11]. Authors and colleagues have reported various papers concerning CR, LCD, glucose profile by continuous glucose monitoring (CGM), meal tolerance test (MTT) and others [12]. Furthermore, we have continued various activities, such as seminars, workshops, books, English medical journals and so on [13]. We established Japan LCD promotion association (JLCDPA) and developed LCD movement medically and socially so far [14]. Authors have continued medical practice in our hospital, and managed various patients with diabetes, PD and others for long [15]. We experienced an impressive case with diabetes and PD. In this article, the case is described with some discussion.

## Case Report

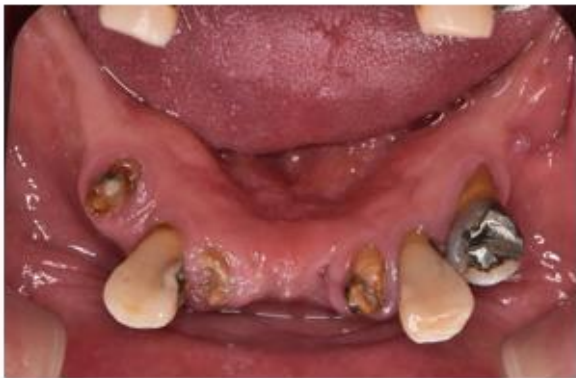### Medical history

The case was 57-year-old male. He has had dental problems that he has a very small number of upper and lower mandibular teeth, then he cannot engage well in mastication. He visited the dental department of our hospital in December 2019. By dental examination, he was diagnosed as periodontal diseases (PD), which was moderate to severe chronic marginal periodontitis. At the same

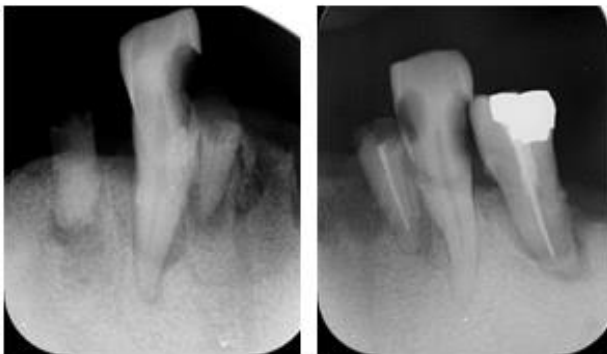
time, the HbA1c level was proved to be 7.8%, and then he was treated in both dentistry and internal medicine departments of the hospital. As to the past history, he had the heart disease of Tetralogy of Fallot (TOF) during his childhood. He had a heart operation at the age of 11, and had spent his days in the children's hospital until 14 years old.

### Physical examination

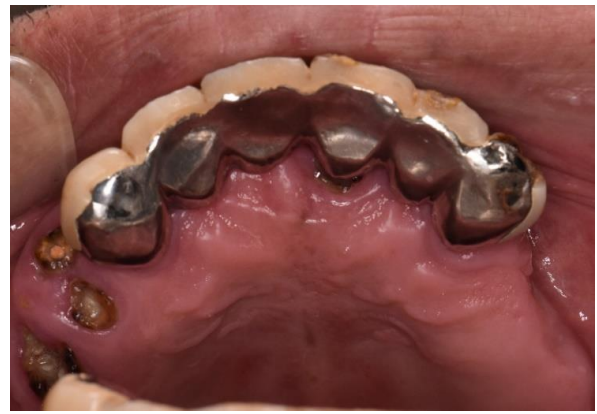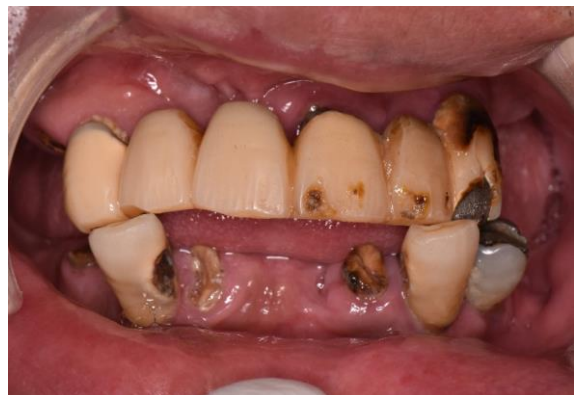His physique showed the first degree of obesity with 172cm, 100kg, BMI 33.8 kg/m<sup>2</sup>. He has no problems about consciousness disorder from hyperglycemia or hypoglycemia. The vital signs were normal. Blood pressure is usually 130/80 with anti-hypertensive agent. His lung, heart, abdomen was unremarkable and no specific diabetic neurological disorders were found.



**Figure 1:** Image of residual teeth in the lower mandibulae.



**Figure 2:** X-ray image of residual teeth in the lower mandibulae (right and left).



**Figure 3:** Image of teeth after temporary splinting treatment

### Dental findings

Among the remaining teeth, the number of occlusal teeth was 2 in the upper jaw and 2 in the lower jaw. Due to the occlusion (engaging) of only the anterior teeth, the teeth were inclined forward and the occlusion situation had collapsed (Figure 1). Plaque was found on all of the remaining teeth. The gingiva was swollen and reddish due to the presence of plaque and calculus deposit with inflammation, and the gingiva showed a dark color. Regarding the condition of gingiva tissues surrounding the storable teeth, moderate to severe periodontal disease and was observed. From these findings, the case has PD and also chronic periapical periodontitis due to carious teeth. XP image of the lower jaw shows bone resorption of PD and bone resorption of root apex due to apical periodontitis. (Figure 2 ). Consequently, he was diagnosed to have chronic marginal periodontitis to moderate to severe degree [16].

### Laboratory examination

Urinalysis showed sugar (++) , protein (-), urobilinogen (+/-). Chest X-P and Electrocardiogram (ECG) were negative. The data of the laboratory tests were as follows: The standard biochemical data were: TP 7.4 g/dL, Alb 4.6 g/dL, AST 20 U/mL, ALT 20 U/mL, AIP 208 U/mL (104-338), r-GT 24 U/mL, BUN 11 mg/dL, Cre 0.8 mg/dL, Uric Acid 5.3 mg/dL, HDL 39 mg/dL, LDL 117 mg/dL, TG 142 mg/dL, WBC 7600 / $\mu$ L, RBC 5.65x 10<sup>6</sup>/ $\mu$ L, Hb 16.5 g/dL, Plt 30.7 x 10<sup>4</sup>/ $\mu$ L, C-reactive Protein (CRP) 0.5 mg/dL . Data related diabetes were HbA1c 7.8%, pre-prandial glucose 162 mg/dL.

### Medical Problems

His health and medical problems could be summarized in the following. They are i) chronic marginal periodontitis (moderate – severe), ii) type 2 diabetes mellitus (T2DM), iii) obesity (172cm, 100kg, BMI 33.8 kg/m<sup>2</sup>), iv) hypertension, v) post-operative state of T/F at 11 years old. Medication included i) Olmesartan medoxomil (Olmotec <sup>R</sup>) 20 mg 1 Tab per day for years and ii) Metformin hydrochloride (Metgluco <sup>R</sup>) 500mg 1 Tab per day from December 2019.

## Clinical Progress

From the dental viewpoint, periodontal treatment included brushing of teeth and removal of calculus on the gingival margin. In parallel, we extracted non-storable teeth with apical periodontitis. For these procedures, the gingival inflammation was relieved from initial status with usual speed of improvement. Successively, temporary splinting under supportive periodontal therapy (SPT) was performed on March 18 [17]. This treatment was successful and so that the dentures allowed the patient mastication in a usual manner (Figure 3). Since subgingival calculus deposit has been present, the treatment of apical periodontitis has been also continued. From internal medicine department, the patient was diagnosed as T2DM. He was advised to start and continue LCD from December, 2019. The detail situation of LCD was super-LCD, where the carbohydrate amount would be less than 14g per meal, and 42g per day. He was encouraged to intake much vegetables, water, eggs, cheese, meat, and other foods with almost no carbohydrate. Regarding his clinical progress, his body weight was reduced 10kg in 3 months (Figure 4).

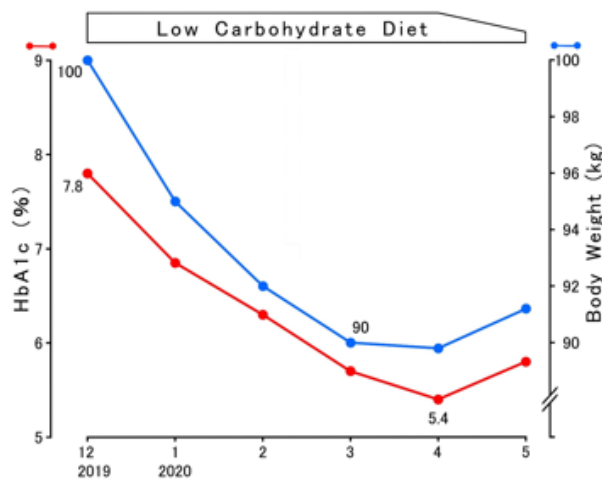


Figure 4: Clinical progress of HbA1c and body weight.

As to HbA1c value, it was reduced from 7.8% to 5.4% in 4 months. Furthermore, value of CRP decreased to 0.2 mg/dL with normal range in 4 months. As LCD was relaxed from super-LCD to standard LCD after April 2020, weight and HbA1c have increased to some extent (Figure 4).

## Ethical considerations

This study was fundamentally conducted with the ethical principles on the Declaration of Helsinki. Further, additional comment was performed by the Ethical Guidelines for Research for Humans, as well as the concept of Good Clinical Practice (GCP). The authors have established an ethical committee, including the president and the director of the hospital, dentist, physician, nurse, nutritionist, pharmacist and that of legal specialty. Discussion has been conducted with valid and appropriate manners, and has decided to the agreements for the

protocol of the research. The informed consent and also written document agreement have been taken from the subject.

## Discussion

This case had chronic marginal periodontitis and diabetes mellitus. The symptoms of periodontitis and diabetes were rapidly improved by both of dental treatment and LCD [4,5]. There are four characteristic points in the following: i) perspective of dental treatment, ii) relationship between dentistry and T/F, iii) relationship between periodontitis and diabetes, and iv) the efficacy of LCD. Those are discussed as below in this order.

Firstly, regarding the engaging of the upper and lower teeth, a normal person can masticate using a total of 28 upper and lower teeth. On the other hand, this case has only four teeth that could be engaged. It is considered that occlusal force has been applied to remaining front teeth too much, and then the teeth has been declined forward [17]. In this case, the plaque control has been unsatisfactory. The cause seems to be from conventionally insufficient tooth brushing. The presence of plaque and calculus contributes to the poor gingival condition. Regarding the swollen and dark gingiva, it may be due to smoking in addition to periodontitis [18].

Secondly, there may be the relationship with Tetralogy of Fallot (T/F). From a previous report, 30 T/F cases were investigated to show cyanosis which caused swelling and discoloration of the gingiva, tongue and lips, associated with clubbing of the fingers [19]. After T/F cases had the operation, the cyanosis may disappear. However, previous insufficient oxygen might influence the swelling of the organ. In this case, the tongue looks larger and the lips tend to be thicker than usual. This manifestation may be the influence of previous T/F.

Thirdly, the relationship among PD, mastication and diabetes would be considered. This case cannot masticate foods to form a bolus in the oral cavity. Then, he was always swallowing food without mastication. As a result, this eating pattern may be involved in the development of obesity and diabetes. Furthermore, this case was suffered from both of periodontitis and diabetes, which has been in focus in dental and medial practice. Several guidelines about diabetes and PD have been found so far. There is the Consensus report and guidelines on PD and diabetes [4,5]. It was proposed from the Perio-diabetes workshop that was organized by International Diabetes Federation (IDF) and also European Federation of Periodontology (EFP). Its content was intended for dental and medical professionals. For dentists, there are important points as follows: i) continue PD monitoring regularly, ii) inform PD patients of the links, iii) ask HbA1c levels, iv) utilize screening questionnaire, v) cooperate internist to lessen diabetes risk. For internists, similar points are as follows: i) inform diabetic patients of the links, ii) ask the symptom of periodontitis possibility, iii) suggest visit to dentist regularly, iv) collaborate dentist and internist together [5].

From the comments mentioned above, some important points are found in the guidelines. They include i) there were insufficient communication between dentists and internists, ii) patients with PD

and diabetes would be treated by both dental and medical offices, iii) average decreased level of HbA1c by effective therapy for PD would be around 2.4 – 2.5% (3-4 mmol/mol) [20,21]. This calculation of conversion unit of HbA1c are from the formula “IFCC level (mmol/mol) = 10.93 × NGSP level (%) – 23.52 (mmol/mol)”. Diabetes has been known as the risk factor for PD for years. The risk level has been about 2-3 times in the diabetics with bad glucose control in comparison with usual healthy people [22]. In addition, PD may bring inflammatory influence of gums and surrounding tissues of alveolar jaw bone [23]. Such continuing inflammation will develop further damage of tissue and teeth loss [22,23]. PD can influence the possibility of metabolic syndrome and cardiovascular diseases with elevated value of CRP. Advanced PD has been the 6<sup>th</sup> prevalent disease in all human diseases worldwide [24]. Advanced PD is found in 8% of adult population in the United Kingdom (UK) according to the National Health Service (NHS) [25].

There has been some investigation concerning PD, CRP and human lifestyle status. Consequently, the level for high sensitivity of CRP showed positive association with PD presence, overweight and daily smoking habit in young generation [26]. Moreover, PD has been reported to show the relationship with the levels of CRP, IL-10 and IL-6 [27]. PD inflammation can be predicted by the HOMA-R level [28]. PD has characteristic mechanism for destroying periodontal tissues and also alveolar bone. Then complex interactions are present between periodontal pathogens and host mechanism for defense ability. As an inflammatory biomarker, CRP has been used for the evaluation of PD and diabetes [29]. According to the consensus guideline of IDF and EFP, the therapy for PD shows clinical effect for patient with diabetes [4]. After PD treatment for 3-4 months, the decreased values of HbA1c by meta-analyses seem to be around 0.27-0.48% [21].

Fourthly, this case showed remarkable efficacy of LCD for the decrease of HbA1c value and body weight. Authors and colleagues have been treating lots of patients with diabetes and obesity. Among them, comparative research on CR and LCD was conducted, where LCD showed clinical efficacy [30,31]. For the meal of CR, the ratio of carbohydrate is about 50-60%. We have also proposed three types of LCDs for everyone to make it easier to practice LCDs in the medical and healthcare fields. They are petite-LCD, standard-LCD and super-LCD with included carbohydrate as 40%, 26% and 12%, respectively [32]. Since any food includes a small amount of carbohydrate, then, the minimum ratio of LCD becomes 12% of carbohydrate included. We have applied LCD on thousands of patients of obesity and diabetes with a remarkable clinical effect [33]. Especially with the application of super-LCD, sufficient weight loss has been obtained in rather short period. This case had also similar satisfactory clinical efficacy.

## Conclusion

This case had the problems of PD and diabetes. Clinical progress showed improvement of inflammatory symptoms and diabetic status. Several factors may be contributed such as dental treatment, LCD, weight loss, rapid improvement of HbA1c and so on. However, there are some limitations and future tasks for this case. The influence of T/F as past history is difficult to consider, and it will be necessary to carefully follow up on the diet, weight, HbA1c, and dental condition. We hope that this case presentation will serve as a reference for clinical practice and research for PD and diabetes.

## References

1. Sakamoto D, Bando H. Recent trend from the clinical point of view for periodontitis and diabetes mellitus. *Dental Res Manag.* 2020; 4: 8-10.
2. Buse JB, Wexle, DJ, Tsapas A, Rossing P, Mingrone G, Mathieu C, et al. 2019 Update to: Management of Hyperglycemia in Type 2 Diabetes, 2018. A Consensus Report by the American Diabetes Association (ADA) and the European Association for the Study of Diabetes (EASD). *Diabetes Care.* 2019.
3. Bando H. Diabetes Mellitus (DM) and Periodontal Disease (PD) with Mutual Vicious Cycle. *Int J Resea Stud Med Health Scie.* 2018; 3: 37-39.
4. Sanz M, Ceriello A, Buysschaert M. Scientific evidence on the links between periodontal diseases and diabetes: consensus report and guidelines of the Joint EFP/IDF Workshop on Periodontal Diseases and Diabetes. *J Clin Periodontol.* 2018; 45: 138-149.
5. Bissett SM, Presseau J, Rapley T, Preshaw PM. Uptake of best practice recommendations in the management of patients with diabetes and periodontitis: a cross-sectional survey of dental clinicians. 2019; 226: 131-137.
6. American Diabetes Association. 9. Pharmacologic Approaches to Glycemic Treatment: Standards of Medical Care in Diabetes-2020. *Diabetes Care.* 2020; 43: 98-110.
7. Atkins RC. Dr. Atkins' new diet revolution Harper New York. 2002.
8. Bernstein R. Dr. Bernstein's diabetes solution Newly revised & Updated. Little Brown and Company New York. 2007.
9. Feinman RD, Pogozelski WK, Astrup A, Bernstein RK, Fine EJ, Westman EC, et al. Dietary carbohydrate restriction as the first approach in diabetes management: Critical review and evidence base. *Nutrition.* 2015; 31: 1-13.
10. Tay J, Thompson CH, Luscombe-Marsh ND, et al. Effects of an energy-restricted low carbohydrate, high unsaturated fat/low saturated fat diet versus a high-carbohydrate, low-fat diet in type 2 diabetes: A 2-year randomized clinical trial. *Diabetes Obes Metab.* 2018; 20: 858-871.
11. Ebe K, Ebe Y, Yokota S, Matsumoto T, Hashimoto M, Sakai Y, et al. Low Carbohydrate diet (LCD) treated for three cases as diabetic diet therapy. *Kyoto Medical Association J.* 2004; 51: 125-129.
12. Bando H, Ebe K, Muneta T, Bando M, Yonei Y. Effect of low carbohydrate diet on type 2 diabetic patients and usefulness of M-value. *Diabetes Res Open J.* 2017; 3: 9-16.
13. Muneta T, Kagaguchi E, Nagai Y, Matsumoto M, Ebe K, Watanabe H, Bando H. Ketone body elevation in placenta, umbilical cord, newborn and mother in normal delivery. *Glycat Stress Res.* 2016; 3: 133-140.

14. Ebe K, Bando H, Yamamoto K, Bando M, Yonei Y. Daily carbohydrate intake correlates with HbA1c in low carbohydrate diet (LCD). *J Diabetol*. 2018; 1: 4-9.
15. Bando H, Abe Y, Sakamoto K, Hatakeyama S, Yagi K, Kobayashi T, et al. Profile of blood glucose in diabetic patient suffered from diabetic foot osteomyelitis with effective low carbohydrate diet. *Diabetes Res Open J*. 2020; 6: 10-16.
16. Suci I, Tarmure V, Ionescu E, Suci I, Chirila M, Gheorghe I, et al. Possible interaction between carious lesions, chronic marginal periodontitis, periapical pathology and salivary iodine level-preliminary results. *Roman Biotechnol Let*. 2018; 23: 13297-13300.
17. Sonnenschein SK, Betzler C, Rütters MA, Krisam J, Saure D, Kim TS. Long-term stability of splinted anterior mandibular teeth during supportive periodontal therapy. *Acta Odontologica Scandinavica*. 2017; 75: 475-482.
18. Mostafa D. An Unusual Habitual Use of an Undiluted Sodium Hypochlorite to Remove Smoking Stains and Calculus: A Case Report. *Stechnolock J Case Rep*. 2020; 1: 9-12.
19. Gedik S, Gedik R, Gedik TN. Tetralogy of Fallot Report of 30 Cases and Dental Considerations with Review of Literature. *WIMJ Open* 2015; 2: 102-105.
20. Simpson TC, Weldon JC, Worthington HV, Needleman I, Wild SH, Moles DR, et al. Treatment of periodontal disease for glycaemic control in people with diabetes mellitus. *Cochrane Database Syst Rev*. 2015.
21. Madianos P, Koromantzios P. An update of the evidence on the potential impact of periodontal therapy on diabetes outcomes. *J Clin Periodontol*. 2018; 45:188-195.
22. Preshaw PM, Alba AL, Herrera D, Jepsen S, Konstantinidis A, Makrilakis K, et al. Periodontitis and diabetes: a two-way relationship *Diabetologia*. 2012; 55: 21-31.
23. O'Dowd LK, Durham J, McCracken GI, Preshaw PM. Patients' experiences of the impact of periodontal disease. *J Clin Periodontol*. 2010; 37: 334-339.
24. Kassebaum NJ, Bernabe E, Dahiya M. Global burden of severe periodontitis in 1990-2010: a systematic review and meta-regression. *J Dent Res*. 2014; 93:1045-1053.
25. White D, Pitts N, Steele JG. *Diseases and Related Disorders*. NHS Information Centre for Health and Social Care, London. 2011.
26. Pitchika V, Thiering E, Metz I, Rothmaier K, Willenberg A, Hickel R, et al. Gingivitis and lifestyle influences on high-sensitivity C-reactive protein and interleukin 6 in adolescents. *J Clin Periodontology*. 2017; 44: 372-381.
27. Aziz AS, Kalekar MG, Suryakar AN, Kale R, Benjamin T, Dikshit M. Pre- and Post-Treatment Effectiveness of SRP on Levels of IL-6, IL-10, and CRP in Chronic Periodontitis Patients with and without Diabetes. *Am J Biochem*. 2018; 8: 1-6.
28. Andriankaja OM, Munoz-Torres FJ, Vivaldi-Oliver J, Leroux BG, Campos M, Joshipura K, et al. Insulin resistance predicts the risk of gingival/periodontal inflammation. *J Periodontol*. 2018; 89: 549-557.
29. Dholey MK, Kole D, Rambabu D, Sen S. Comparative estimation of salivary and serum C-reactive protein levels in chronic periodontitis with or without Type II diabetes mellitus: A clinico-biochemical study. *SRM J Res Dent Sci*. 2017; 8: 99-104
30. Bando H, Ebe K, Muneta T, Bando M, Yonei Y. Difference of Glucose variability between Low Carbohydrate Diet (LCD) and Calorie Restriction (CR). *Asp Biomed Clin Case Rep*. 2018; 2: 4-15.
31. Ebe K, Bando H, Muneta T, Bando M, Yonei Y. Remarkable improvement of glucose variability by Sodium-glucose cotransporter 2 (SGLT2) inhibitors using continuous glucose monitoring (CGM). *Diabetes Case Rep*. 2019; 4:1.
32. Bando H. Useful Tips for Actual Low Carbohydrate Diet (LCD) with Super-Standard-and Petit-LCD Methods. *EC Nutrition*. 2020.
33. Nakamura T, Bando H, Kawashima T, Dobashi M, Narita A. Weight Reduction by Effective Protocol of Diet and Exercise. *J Diab Obes Metab*. 2019; 2: 106.