

# Impressive clinical course of diabetic patient with various medical problems and remarkable improvement by insulin degludec and liraglutide (Xultophy)

## Abstract

Diabetes mellitus causes macrovascular, microvascular angiopathy, and increased cancer risk. Authors et al. have continued clinical practice and research on diabetes cases. Current case is impressive 79-year-old female with various diseases. They include asthma and COPD, steroid intake for years, sleep apnea syndrome (SAS), Continuous Positive Airway Pressure (CPAP) therapy, tongue cancer, arteriosclerosis, bone complications, Carpal tunnel syndrome (CTS), and so on. When she developed hyperglycemia with 9.0% of HbA1c, Xultophy® was started. It contains insulin degludec and liraglutide which is Glucagon-like peptide-1 receptor agonist (GLP-1 RA). HbA1c values decreased as 7.9%, 7.3%, 6.9%, 6.5% in 1-4 months, with remarkable effect. The satisfactory efficacy may be from double agents of Xultophy® or probable secondary diabetes due to continuation of steroid of the case. This report will be expected to be some reference in the future diabetic research development.

**Keywords:** Xultophy®, glucagon-like peptide-1 receptor agonist (GLP-1 RA), Japan LCD promotion association (JLCDPA), Carpal tunnel syndrome (CTS), oral hyperglycemic agents (OHAs)

Volume 10 Issue 2 - 2020

Yoshikane Kato,<sup>1</sup> Hiroshi Bando,<sup>1,2</sup> Hisako Yamashita,<sup>1</sup> Seigo Yada,<sup>1</sup> Shunsuke Tokuhara,<sup>1</sup> Hatsue Tokuhara,<sup>1</sup> Teruo Mutsuda<sup>1</sup>

<sup>1</sup>Kanaiso Hospital, Komatsushima, Japan  
<sup>2</sup>Tokushima University, Medical Research, Japan

**Correspondence:** Hiroshi Bando, Kanaiso Hospital, Komatsushima, Japan, Tel +81-90-3187-2485, Fax +81-88-603-1030, Email pianmed@bronze.ocn.ne.jp

**Received:** April 20, 2020 | **Published:** April 30, 2020

**Abbreviations:** GLP-1 RA, Glucagon-like peptide-1 receptor agonist; JLCDPA, Japan LCD promotion association; CTS, Carpal tunnel syndrome; OHAs, oral hyperglycemic agents

## Introduction

Across the world, diabetes mellitus has been one of the important diseases for its various impact to medical and social aspects<sup>1</sup> The prevalence is now increasing more in developing and developed countries. Diabetic state has to be controlled in order to protect several chronic complications.<sup>2</sup> They include macrovascular angiopathy such as brain, heart, foot, microvascular angiopathy such as neuropathy, retinopathy and nephropathy, as well as increased cancer risk (relative ratio: 1.19/1.27 in M/F).<sup>2,3</sup> There have been three kinds of principles for the therapy of the diabetes. They are i) adequate diet therapy, ii) aerobic exercise therapy, and iii) pharmacotherapy including oral hyperglycemic agents (OHAs) and injection method for diabetes.<sup>4</sup>

Regarding the diet therapy, current topics include the gradual changes from calorie restriction (CR) to low carbohydrate diet (LCD). Formerly, LCD was initiated by Atkins, Bernstein and others in medical and health fields.<sup>5</sup> The trend was gradually known and prevalent in North American and European area. Further, several reports comparing the effects among CR, LCD and Mediterranean diet have been on discussion.<sup>6</sup> LCD has been evaluated as more effective method for metabolic syndrome including obesity, diabetes and so on.<sup>7</sup> Successively, some discussion has been found concerning the definition of several types of LCD nowadays.<sup>8</sup>

On the other hand, the authors and collaborators have started LCD at first in Japan.<sup>9</sup> We have continued developing LCD movement

through Japan LCD promotion association (JLCDPA).<sup>10</sup> For diabetic research, we have reported several papers on LCD, comparison of LCD and CR, blood glucose profiles, increased ketone bodies, continuous glucose monitoring (CGM), meal tolerance test (MTT), and others.<sup>11</sup> Furthermore, various reports about diabetic complications have been presented so far.<sup>12,13</sup> Recent topics for medication include new agents such as Dipeptidyl peptidase 4 (DPP-4) inhibitors and glucagon-like peptide-1 receptor agonist (GLP-1 RA).

Among our clinical practice, we experienced an impressive female diabetic patient. She has various medical problems, diabetic complications, continuous intake of steroid for years and has remarkable effect to new injection agent Xultophy® including both of insulin and GLP-1 RA. General clinical course of the case and some discussion are described in this article.

## Case report

### Present history

The case was 79-year-old female patient with multiple kinds of diseases. Originally, she has been obese from 45 years old, and suffered from bronchial asthma and chronic obstructive pulmonary disease (COPD) from 56 years old. The asthmatic attack was rather frequent, then she was provided steroids for long. The dose was 7.5-10mg/day of prednisolone and other agents of theophylline was also continued. Furthermore, she showed several symptoms of sleep apnea syndrome (SAS) from 75 years. Then she has been treated for Continuous Positive Airway Pressure (CPAP) at night for 4 years. Her physique had been 145cm, 62-65kg, BMI 29.5- 30.9.

For last few years, she has suffered from additional several diseases. She fell and had a left medial femoral detachment fracture on May 2018. At that time, her value of young adult mean (YAM) was 75% with rather decreased bone mineral density (BMD), and she was diagnosed as osteopenia. She was started to be given Ibandronate sodium hydrate (Bonviva Syringes®, ATC code: M05BA06) once per month.

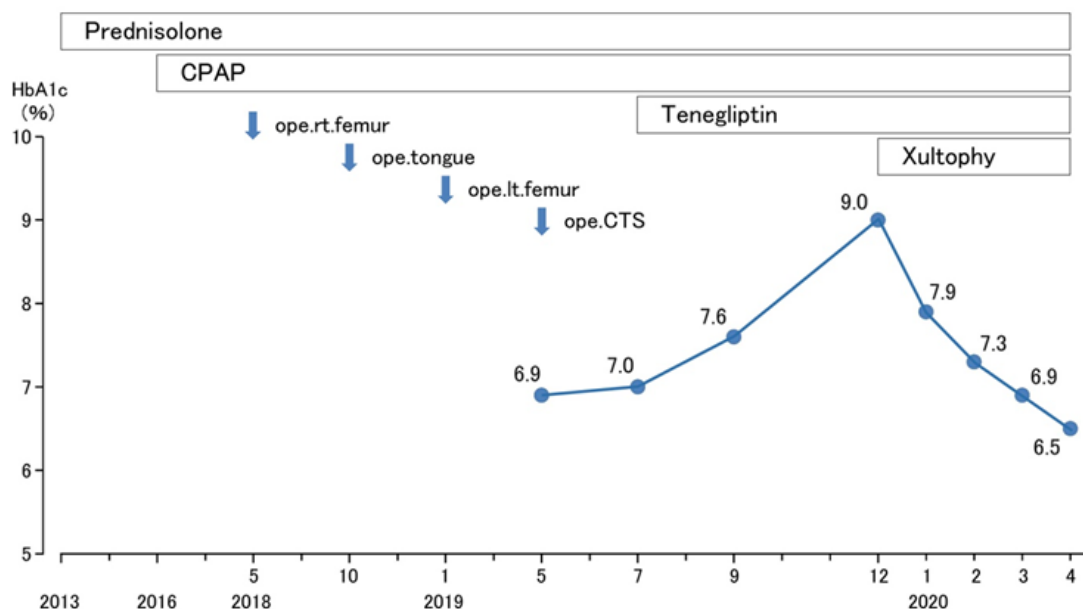
She developed discomfort in the oral cavity and tongue in October, 2018. Further evaluation revealed that she had a tongue cancer. Then, she had an operation for finger-tip sized tumor, which was successfully performed in December, 2018. She fell again in January 2019. She was diagnosed to have a left femoral neck fracture, atrial fibrillation (Af), hypertension and previous cerebral vascular accident (CVA). Then she was provided the operation of the femoral bone and the administration of anti-coagulant agents.

After that, she had felt the numbness and diminished grip strength in her left hand. She was diagnosed as left median nerve palsy (Carpal

tunnel syndrome, CTS), and had the operation in May, 2019. After the operation, her HbA1c was followed up, which was 7.0% in July. Then she was started to have DPP-4 inhibitor teneligliptin hydrobromide hydrate (Tenelia®).

However, HbA1c was exacerbated to 7.6% in September, and 9.0% in December. Consequently, she was started to have Xultophy®, which has both of insulin degludec and liraglutide (xultophy® 100/3.6) Pen. Standard dose is usually 10 dose/ one injection, including degludec 10 units and liraglutide 0.36 mg. In this case 5 dose was injected once per day. Her body weight was 66kg in December.

Consequently, the HbA1c value has been reduced as followed: 7.9% in January, 7.3% in February, 6.9% in March and 6.5% in April, 2020. At that time, her weight was 64kg. Summarized these situations above, Figure 1 showed the clinical course of history, HbA1c value and several kinds of treatments.



**Figure 1** Clinical course of various episodes, treatments and the changes in HbA1c value.

### Physical examination

Her physicals on September 2019 were as follows: consciousness was alert, the vitals were pulse 80/min, BP 140/86mmHg, SpO<sub>2</sub> 97%, BT 36.7C°, respiration was normal, body stature 145cm, body weight 64kg, Body Mass Index (BMI) 30.4kg/m<sup>2</sup>. Lung sound was a little harsh, heart showed no significant murmurs, abdomen is unremarkable. She showed negative neurological abnormalities.

### Several examination

Laboratory exams were performed on September 2019. CBC showed that RBC 4.49x10<sup>6</sup>/μL, Hb11.5g/dL, WBC 9500/μL, Plt 27.3x10<sup>4</sup>/μL, Biochemistry showed that TP 6.6g/dL, Alb 4.0g/dL, BUN 24mg/dL, Cre 0.9mg/dL, eGFR 43mL/min, T-Bil 0.4mg/dL, AST 21U/L, ALT 20U/L, ALP 138 U/L (100-340), LDH 244U/L (110-210), CK 124U/L (30-150), C-reactive Protein (CRP) 0.08mg/dL, blood glucose 187mg/dL, HbA1c 7.6%.

She had basal screening examinations. Chest X-ray showed a little emphysematous change and electrocardiogram (ECG) revealed atrial

fibrillation (Af). Abdominal X-ray was negative and abdominal CT scan showed moderate fatty liver. Urinalysis showed that protein (-), glucose (+), urobilinogen (+/-). She has showed unremarkable findings in retinopathy, neuropathy and nephropathy.

### Problem lists

- #1 Obesity (45 years old)
- #2 Bronchial asthma and COPD (56 yo)
- #3 continuation of prednisolone (56 yo)
- #4 CPAP treatment (75 yo)
- #5 tongue cancer (77 yo)
- #6 atrial fibrillation (Af), hypertension (77 yo)
- #7 previous CVA(77 yo)
- #8 osteopenia and bone fracture (77 yo)
- #9 Carpal tunnel syndrome (CTS) (78 yo)

#10 Diabetic state (79 yo)

#11 administration of Xultophy® (79 yo)

## Treatment of problems

According to the problems mentioned above, treatments of these problems are summarized as follows.

- i. Asthma, COPD and CPAP (#2-4): ambroxol hydrochloride (Mucosolvan L®) 45mg/day as an Airway lubricant, prednisolone (Predonine®) 10mg/day as steroids (#3), theophylline (Theolong®) 400mg/day as a Xanthine derivative, and fluticasone propionate 50µg and formoterol fumarate hydrate 5µg (Flutiform Aerosol®)x2 doses/day as long acting beta 2 stimulator. CPAP has been continued for 4 years (#4).
- ii. Af and hypertension (#6): rivaroxaban (Lixiana®) 30 mg/day as a direct oral anticoagulant (DOAC), verapamil hydrochloride (Vasolan®) 240mg/day as a Ca blocker (class IV) and spironolactone (Aldactone-A®) 25mg/day
- iii. previous CVA (#7):rivaroxaban (Lixiana®) 30mg/day as a direct oral anticoagulant (DOAC)
- iv. osteopenia and bone fracture(#8): Ibandronate sodium hydrate (Bonviva Syringes®)
- v. Diabetes and Xultophay® (#10,11):teneligliptin hydrobromide hydrate (Tenelia®) 20mg/day, as DPP-4 inhibitor and Xultophay® including both of insulin degludec and liraglutide (xultophy®100/3.6) Pen. In this case 5 dose was injected once per day, which includes degludec 5 units and liraglutide 0.18 mg.

## Discussion

In this report, the case associated with a variety of medical problems was described. These problems are discussed in the order of the medical problems in the following. As the underlying diseases, the case had bronchial asthma and COPD (#2). For this treatment, steroid therapy was indispensable because theophylline treatment alone was not effective (#3). The continuation of steroid for years may have involved other medical problems.

Regarding CPAP (#4), it was started four years ago because of the presence of Obesity and COPD (#1, #2). CPAP situation seemed to be stable as a result of the investigation. CPAP report was shown as follows: PAP mean pressure of 8.1cm H<sub>2</sub>O, a maximum PAP pressure of 9.3cm H<sub>2</sub>O, a mean large leak of 2 minutes 18 seconds and an apnea hypopnea index (AHI) of 1.2.

The case had tongue cancer in the category of Oral squamous cell carcinoma (OSCC)(#5). OSCC has been most frequently found in tongue, neck and head region.<sup>14</sup> There was an experimental steroidogenic model for OSCC in translational research. As a result, the development of the target and gene of OSCC would be involved in various influencing factors such as Cancer Stem Cells (CSCs), Endothelial Growth Factor Receptor (EGFR), Progesterone Receptor (PR) and Estrogen Receptor (ER).<sup>14</sup>

From previous studies, diabetes seems to promote the activation of the Ras/Raf/MAPK signal transduction pathway.<sup>15</sup> It is mainly induced by erbB2 and erbB3 receptors, which leads to stimulating cell proliferation.

About a year ago, Af, hypertension and previous CVA have been pointed out (#6, #7). Her medical history shows that those were not found before. It may be suggested from the development of

arteriosclerosis such as worsening of obesity, potential progress for high blood pressure and high blood glucose.

The case showed osteopenia with 75% of young adult mean (YAM) value (#8). According to the standard guideline, the bone mineral density (BMD) was classified as normal in 80% or more of YAM, 70%-80% as osteopenia, and less than 70% as osteoporosis.<sup>16</sup>

Later the case developed fractures of the femur. These onsets may be involved in several factors, such as obesity (# 1), long-term administration of steroids (#3), postmenopausal female hormone decline, and others. Regarding the risk of the relationship between hip fracture (#8) and use of oral corticosteroid, there was a case-control study. For 14 years, cases with hip fracture (n=4538) were compared with cases without fracture (n=4538). As a result, the odds ratio (OR) was proved to be 1.17.<sup>17</sup>

Carpal tunnel syndrome (CTS) has been a common medical problem (#9), which remains most frequently reported from median nerve compression. Their risk factors may include obesity, pregnancy, monotonous wrist activity, rheumatoid inflammation, genetic heredity, and so on.<sup>18</sup> In current case, she has obesity and diabetes as fundamental diseases. For diabetic cases, the incidence of carpal tunnel syndrome has been 14% for those without diabetes, and 30% for those with diabetic neuropathy.<sup>18</sup> On the other hand, during pregnancy it would be reduced to about 2% in prevalence rate.<sup>19</sup>

There was a meta-analysis concerning the relationship between diabetes and CTS.<sup>20</sup> From studies from 1950 to 2015, 25 studies with 92564 cases were investigated. The estimated OR was 1.97 (95% CI 1.56–2.49) for unadjusted situation and 1.69 (95% CI 1.45–1.96) for controlling potential confounders. The results do not differ between type 1 and type 2.<sup>20</sup>

The case showed hyperglycemia, and rapid improvement of diabetic state after starting Xultophy(#10, #11). There are two current standard guidelines for diabetes, which are the American Diabetes Association (ADA) Standards of Medical Care in Diabetes 2020<sup>21</sup> and the 2019 “Consensus Statement by the American Association of Clinical Endocrinologists (AACE) and American College of Endocrinology (ACE) on the Comprehensive Type 2 Diabetes Management Algorithm”.<sup>22</sup> Both guidelines have recommended physicians to consider the combination of injection treatment for post-prandial hyperglycemia in the cases who show basal insulin doses 0.5units/kg/day with higher HbA1c level.<sup>21</sup>

Xultophy® includes insulin and Glucagon-like peptide-1 receptor agonist (GLP-1 RA). When Xultophy® (100/3.6) is injected, 1 unit contains 1 unit of insulin degludec and 0.036mg of liraglutide.<sup>23</sup> It can be injected from 10-50 units. The Xultophy® pen is prefilled by 300 units of Xultophy® 100/3.6 (300 units insulin degludec/10.8mg liraglutide). It has no push-button extension, and the dose button does not extend while dialing the amount, no matter how the dose is.<sup>23</sup> It has once-daily regimen, and shows less hypoglycemia or weight gain compared with intensive insulin regimens. Furthermore, it shows reduced gastrointestinal (GI) adverse effects compared with GLP-1 RA alone.<sup>23,24</sup>

In this case, administration of Xultophy brought a sharp decrease in HbA1c, and clinical remarkable effect was observed. One of the reasons is that it would be secondary diabetes due to taking steroids for many years. Therefore, the function ability of insulin secretion may be not so exhausted. However, all of endocrinological evaluation in detail was not been performed yet at this time.

Current study has some limitations. A variety of medical problems were found in this case. It may be related to taking steroids for years, but all pathophysiological studies have not been conducted. For diabetes, it is planned to check C-peptide values in blood and urine, diurnal blood glucose fluctuation, reactivity to glucose loading, associated with current data of obesity, hypertension, dyslipidemia, uric acid, and so on.

In summary, this case seemed to be impressive from several points of view. They include asthma and COPD, CPAP therapy, tongue cancer, arteriosclerosis, bone complications, CTS and administration of Xultophy®. Many years of steroid administration may be influenced the progress. We hope that this report will serve as a reference for future diabetes practice.

## Ethical considerations

Current case report was conducted in compliance with the fundamental ethical principles of the Declaration of Helsinki. Further, this was also with Japan's Act on the Protection of Personal Information. It was along with the Ministerial Ordinance on Good Clinical Practice (GCP) for Drug, which was presented by the Ordinance of Ministry of Health and Welfare No. 28 of March 27, 1997.

As regard to this study, authors have established an ethical committee in the Kanaiso Hospital. It included the president, the director of the hospital, the head-nurse of the nursing department, director of the Pharmaceutical department, and expert in the medical/legal specialty. We have discussed enough and made the confirmation that this study was valid and agreed with all members with no problems. Moreover, an informed consent and written paper agreement have been obtained from the subject.

## Conflicts of interest

The authors declare that they have no conflicts of interest.

## Acknowledgments

Authors would like to appreciate all of staffs, patient and related people for current investigation.

## Funding

The authors do not have any funding concerning our medical research.

## References

1. International Diabetes Federation. *Diabetes Atlas*. 8th ed. 2019.
2. Mauricio D, Alonso N, Gratacòs M. Chronic Diabetes Complications: The Need to Move beyond Classical Concepts. *Trends in Endocrinology & Metabolism*. 2020;31(4):287–295.
3. Ohkuma T, Peters SAE, Woodward M. Sex differences in the association between diabetes and cancer: a systematic review and meta-analysis of 121 cohorts including 20 million individuals and one million events. *Diabetologia*. 2018;61(10):2140–2154.
4. American Diabetes Association. Pharmacologic approaches to glycemic treatment: Standards of Medical Care in Diabetes. 2019. *Diabetes Care*. 2019;42(1):S90–S102.
5. Bernstein RK. *Dr. Bernstein's Diabetes Solution*. Little, Brown and company, New York. 1997.
6. Shai I, Schwarzfuchs D, Henkin Y, et al. Dietary Intervention Randomized Controlled Trial (DIRECT) Group. Weight Loss with a Low-Carbohydrate, Mediterranean, or Low-Fat Diet. *N Engl J Med*. 2008;359:229–241.
7. Feinman RD, Pogozelski WK, Astrup A, et al. Dietary carbohydrate restriction as the first approach in diabetes management: Critical review and evidence base. *Nutrition*. 2015;31(1):1–13.
8. Tay J, Thompson CH, Luscombe Marsh ND, et al. Effects of an energy-restricted low carbohydrate, high unsaturated fat/low saturated fat diet versus a high-carbohydrate, low-fat diet in type 2 diabetes: A 2-year randomized clinical trial. *Diabetes Obes Metab*. 2018; 20(4):858–871.
9. Ebe K, Ebe Y, Yokota S, et al. Low Carbohydrate diet (LCD) treated for three cases as diabetic diet therapy. *Kyoto Medical Association Journal*. 2004;51:125–129.
10. Muneta T, Kagaguchi E, Nagai Y, et al. Ketone body elevation in placenta, umbilical cord, newborn and mother in normal delivery. *Glycat Stress Res*. 2016;3(3):133–140.
11. Bando H, Ebe K, Muneta T, et al. Effect of low carbohydrate diet on type 2 diabetic patients and usefulness of M-value. *Diabetes Res Open J*. 2017;3(1):9–16.
12. Kato Y, Bando H, Yamashita H, et al. Seasonal changes in HbA1c values from young to elderly diabetic patients. *J Diabetes Metab Disord Control*. 2019;6(3):89–92.
13. Shimizu E, Takehisa Y, Bando H, et al. Effective SGLT2 Inhibitor for Patient with Type 2 Diabetes Mellitus (T2DM) and Depression. *Diab Res Open Access*. 2020;14;2(S1):26–32.
14. Boccellino M, Di Stasio D, Dipalma G et al. Steroids and growth factors in oral squamous cell carcinoma: useful source of dental-derived stem cells to develop a steroidogenic model in new clinical strategies. *Eur Rev Med Pharmacol Sci*. 2019;23(20):8730–8740.
15. Vairaktaris E, Spyridonidou S, Goutzanis L, et al. Diabetes and oral oncogenesis. *Anticancer Res*. 2007;27(6):4185–4194.
16. Orimo H, Nakamura T, Hosoi T, et al. Japanese 2011 guidelines for prevention and treatment of osteoporosis—Executive summary. *Archives of Osteoporosis*. 2012;7:3–20.
17. Lai SW, Lin CL, Liao KF. Use of Oral Corticosteroids and Risk of Hip Fracture in the Elderly in a Case-Control Study. *Frontiers in Pharmacology*. 2017;8:625.
18. Genova A, Dix O, Saefan A, Thakur M, et al. Carpal Tunnel Syndrome: A Review of Literature. *Cureus*. 2020;12(3):e7333.
19. Becker J, Nora DB, Gomes I, et al. An evaluation of gender, obesity, age and diabetes mellitus as risk factors for carpal tunnel syndrome. *Clin Neurophysiol*. 2002;113(9):1429–1434.
20. Pourmemari MH, Shiri R. Diabetes as a risk factor for carpal tunnel syndrome: a systematic review and meta-analysis. *Diabetic Medicine*. 2015;33(1):10–16.
21. American Diabetes Association. 9. Pharmacologic approaches to glycemic treatment: Standards of Medical Care in Diabetes—2020. *Diabetes Care*. 2020;43(Suppl. 1):S98–S110.
22. Garber AJ, Abrahamson MJ, Barzilay JI, et al. Consensus statement by the American Association of Clinical Endocrinologists and American College of Endocrinology on the comprehensive type 2 diabetes management algorithm: 2019 executive summary. *Endocr Pract*. 2019;25(1):69–100.
23. Homepage of Xultophy®.
24. Melzer-Cohen C, Chodick G, Naftelberg S, et al. Metabolic Control and Adherence to Therapy in Type 2 Diabetes Mellitus Patients Using IDegLira in a Real-World Setting. *Diabetes Ther*. 2020;11(1):185–196.