

## Clinical Utility of Reconstruction Image of Computed Tomography Scan

Ogura K<sup>a</sup>, Kato Y<sup>a</sup>, Kawata T<sup>a</sup>, Irikawa M<sup>a</sup> and Bando H<sup>b\*</sup>

<sup>a</sup>Kanaiso Hospital, Komatsushima, Tokushima, Japan

<sup>b</sup>Tokushima University / Medical Research, Japan

### Article Info

#### Article History:

Received: 29 October, 2019

Accepted: 01 November, 2019

Published: 08 November, 2019

\*Corresponding author: Bando H, Tokushima University /Medical Research, Nakashowa 1-61, Tokushima 770-0943, Japan; Tel: +81-90-3187-2485; Fax: +81-88-603-1030; E-mail: [pianomed@bronze.ocn.ne.jp](mailto:pianomed@bronze.ocn.ne.jp)

### Abstract

Computed tomography (CT) has been utilized in the clinical practice across the world. It was introduced in 1972, and has been evolved for indispensable diagnostic examination for long. CT scan exams have been prevalent and increased to 80 million a year in United States.

**Keywords:** CT scan; Reconstruction image; Computed tomography (CT); Colorectal cancer (CRC); Degenerative spondylolisthesis

**Copyright:** © 2019 Ogura K, et al. This is an open-access article distributed under the terms of the Creative Commons Attribution License, which permits unrestricted use, distribution, and reproduction in any medium, provided the original author and source are credited.

### Introduction

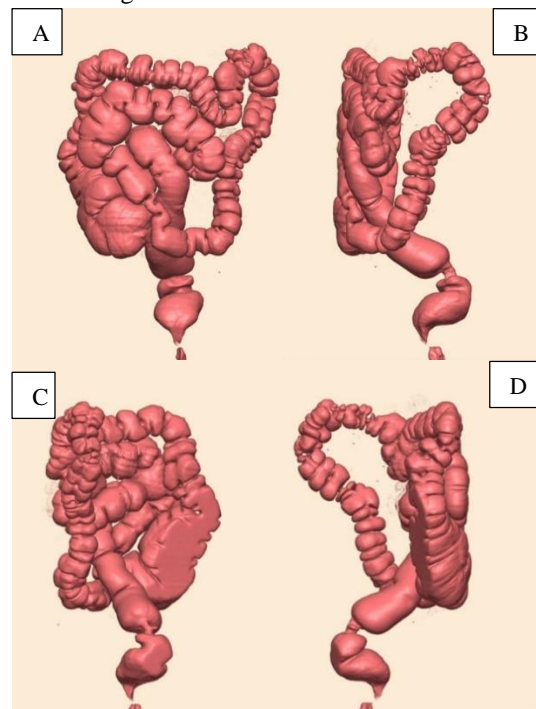
Computed tomography (CT) has been utilized in the clinical practice across the world [1]. It was introduced in 1972 [2], and has been evolved for indispensable diagnostic examination for long. CT scan exams have been prevalent and increased to 80 million a year in United States [3]. CT images were originally reconstructed by iterative method, which was algebraic reconstruction technique (ART) [4]. However, it did not have enough computational power, then it was replaced by the simple analytic method of filtered back projection (FBP). FBP was used for rather long period until the next generation. After that, there have been the evolutions of iterative reconstruction (IR) technique. After that, IR algorithms have been used for medical practice, and there would be recently further development such as photon-counting CT [5] and artificial intelligence (AI) [6]. Thus, CT reconstruction technology has been developed so far. We have been treating various patients for many years. Among them, some cases in which CT reconstruction contributed the diagnosis and treatment would be described in this article.

### Subjects and Methods

#### Case 1 presentation

An 86-year-old man has been hypertensive, who was treated by Amlodipine besilate 2.5 mg/day for years. He developed constipation and abdominal fullness, and then he had further evaluation. His blood and biochemical tests revealed that Hb 12.4 g/dL, TP 6.4 g/dL, GOT 39 U/L, GPT 23 U/L, HDL 75 mg/dL, LDL 117 mg/dL, TG 89 mg/dL, Cre 1.1 mg/dL, HbA1c 5.9%, CEA 2.9 ng/ml. He received colonofiberscopic examination, but the fiberscope could not go forward because of the stenosis in the colon. In order to clarify the general status of colon, abdominal CT scan was performed associated with blowing in the air. The

results showed the image of the apple core, which is characteristic finding of colorectal cancer (CRC). The case was diagnosed to have sigmoid cancer (Figure 1). This image can be observed from any angle of 360 degree (Figures 1A-1D). Thus, the general image of the whole status of the colon can be detected by the reconstruction image of CT scan.

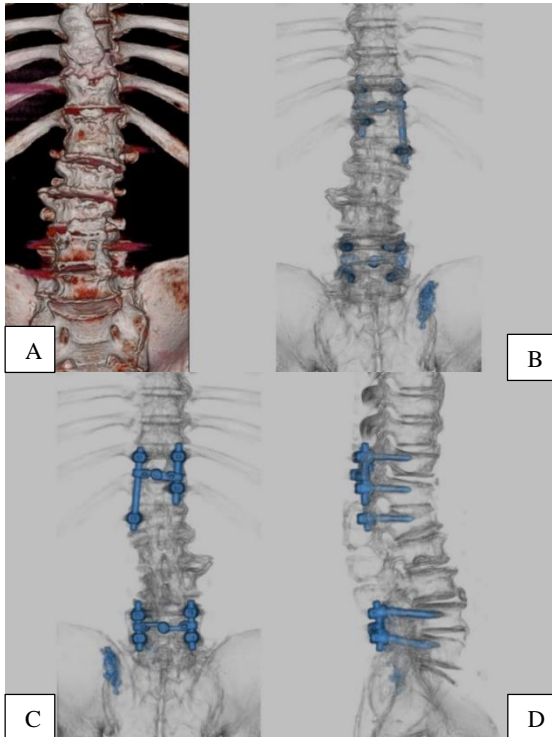


**Figure 1:** Reconstruction image of colon in case 1; 1A: It does not show clear image of the presence of cancer. 1B: Apple core sign can be observed clearly, suggesting the Presence of cancer. 1C: The posterior aspect of the lesion can be observed. 1D: It shows clear image of apple core sign from other direction.

#### Case 2 presentation

A 71-year-old man has initially presented several medical

problems. He had been treated as hypertension, hyperlipidemia and gastroesophageal reflux disease (GERD) at the internal medicine department. Furthermore, he has complained of chronic lower back pain, right sciatica and abnormal gait in the orthopedic department. His history and findings showed degenerative spondylolisthesis at Th11-12-L1 and L4-5 with severe canal stenosis. His blood and biochemical tests revealed normal, which were Hb 15.6 g/dL, TP 6.7 g/dL, AST 16 U/L, ALT 13 U/L, TG 75 mg/dL, HDL 67 mg/dL, Cr 0.7 mg/dL, HbA1c 5.5%. He has received orthopedic operation with pedicle screws and rods at those impaired position. After the operation, the reconstruction image of the vertebrae was evaluated (Figure 2a and 2b). Figure 2b presented the image from anterior to posterior direction, in which the screws and rods are not so clearly observed. On the other hand, Figure 2c and 2d presented the image from posterior-anterior and lateral directions, in which the screws and rods can be clearly observed. Such combined images would give detail data of vertebrae and contribute much for the patient.



**Figure 2:** Reconstruction image of lumbar region in case 2; 2A: There are deformity of the spine and the artifacts from the Presence of the metal. 2B: When focusing the screws and rods, the image can become clearer. 2C: The image of the pedicle screws can be clearly observed from posterior aspect. 2D: Lateral aspect shows the detail position of the screws and rods.

## Methods

The apparatus of the CT scan was Toshiba Alexion 16 CT Scan Machine (Toshiba/Canon in Japan) [7]. It is spiral type with 16 slice system and scan time at 0.75, 1, 1.5, 2 and 3 seconds. The details of the product show that the 0.5 mm detector elements (the

smallest in current CT technology) provide razor-sharp images, ensuring fast and accurate diagnosis in all parts of the body with a lower exposure dose. It includes multiplanar reconstruction or reformation (MPR), such as 3D Color Image Processing, 3D surface rendering, 3D volume rendering, Cine display and Curved MPR [8]. Making the most of this method, the reconstruction image of the CT scan has been analyzed and made for clinically beneficial practice.

## Discussion

CT reconstruction has been useful for examining the images of gastrointestinal system. In Case 1, the entire colon could not be observed due to the stenosis, but the general condition of the entire colon could be revealed by CT reconstruction image technique. CT colonography has been beneficial for the preoperative assessment of CRC [9]. Especially, the effect of model-based iterative reconstruction for image quality has been recognized. Furthermore, the detection for the minute lesion of CRC has been possible by Ultralow-dose CT colonography associated with iterative model reconstruction image technique [10]. The method of 3D reconstruction seemed to be beneficial for medical diagnosis and management in also case 2. Especially, 3D reconstruction does not require IV contrast procedure, then it is also useful for the patient with renal impairment. Thus, 3D reconstruction image of post-operative CT data has been useful for evaluating the current status and the treatment with demonstrating actual implant position of the bolts [11]. Furthermore, pre and post-operative planning associated with 3D analysis and biomodelling would be further beneficial for surgical techniques / equipment and future management. In relation to the reconstruction image of CT scan, 3D printing has been one of the excellent technology with a wide range of applications [12]. In addition to the medical region, there have been various applicable opportunities, such as dental, biological, mechanic region, there have been a variety of opportunities. In the medical practice, surgical models have been used for the preparation of the operation, with shortening operative time and decreasing the risk [12-13]. The method of 3D printing has been prevalent until now, in the case of spinal surgery [14], osteogenesis imperfect [15], and so on. There was a comparative study that patients with degenerative lumbar diseases were randomized into three groups [16]. They include the educational program by i) CT & MRI imaging, ii) 3D reconstructions, and iii) personalized 3D printed models. Among them, group iii) showed higher understanding level than i) and ii) [16]. In summary, the reconstruction image of CT scan for several useful applications was described in this article. Further development of clinical practice and research would be expected in association with the application of 3D printer in the future.

## Acknowledgement

The authors would like to express our gratitude to the patients, all staffs of the hospital and all related people for the understanding and cooperation.

## References

1. Willemink MJ, Noel PB. The evolution of image reconstruction for CT-from filtered back projection to artificial intelligence. *Eur Radiol.* 2018; 29: 2185-2195.
2. Ambrose J, Hounsfield G. Computerized transverse axial tomography. *Br J Radiol.* 1973; 46: 148-149.
3. OECD. Health at a glance 2017: OECD indicators. OECD Publishing, Paris. 2017.
4. Fleischmann D, Boas FE. Computed tomography-old ideas and new technology. *Eur Radiol.* 2011; 21: 510-517
5. Willemink MJ, Persson M, Pourmorteza A, Pelc NJ, Fleischmann D. Photon-counting CT technical principles and clinical prospects. *Radiology.* 2018; 289: 1-2.
6. Wolterink JM, Leiner T, Viergever MA, Isgum I. Generative adversarial networks for noise reduction in low-dose CT. *IEEE Trans Med Imaging.* 2017; 36: 2536-2545.
7. For general customers.
8. Toshiba Alexion 16 CT scan Machine for Hospital.
9. Taguchi N, Oda S, Imuta M, Yamamura S, Nakaura T, Utsunomiya D, et al. Model-based Iterative Reconstruction in Low-radiation-dose Computed Tomography Colonography. *Academic Radiol.* 2018 25: 415-422.
10. Lambert L, Ourednicek P, Briza J, Giepmans W, Jahoda J, Hruska L, et al. Sub-milliSievert ultralow-dose CT colonography with iterative model reconstruction technique. 2016.
11. Thayaparan GK, Owbridge MG, Thompson RG, Urso DPS. Designing patient-specific solutions using biomodelling and 3D-printing for revision lumbar spine surgery. *Eur Spine J.* 2018; 28: 18-24.
12. Shafiee A, Atala A. Printing technologies for medical applications. *Trends Mol Med.* 2016; 22: 254-265.
13. Malik HH, Darwood ARJ, Shaunak S, Kulatilake P, El-Hilly AA, Mulki O, et al. Three-dimensional printing in surgery: a review of current surgical applications. *J Surg Res.* 2015; 199: 512-522.
14. Peng P. Is a patient-specific drill template via a cortical bone trajectory safe in cervical anterior transpedicular insertion. *J Orthop Surg Res.* 2018; 13: 91.
15. Eisenmenger LB, Wiggins HR, Fults WD, Huo EJ. Application of 3-Dimensional printing in a case of osteogenesis imperfecta for patient education, anatomic understanding. Preoperative planning and intraoperative evaluation. *World Neurosurg.* 2017; 107: 1049-1056.
16. Zhuang Y, Zhou M, Liu S, Wu J, Wang R, Chen C. Effectiveness of personalized 3D printed models for patient education in degenerative lumbar disease. *Patient Education and Counseling.* 2019; 102:1875-1881.